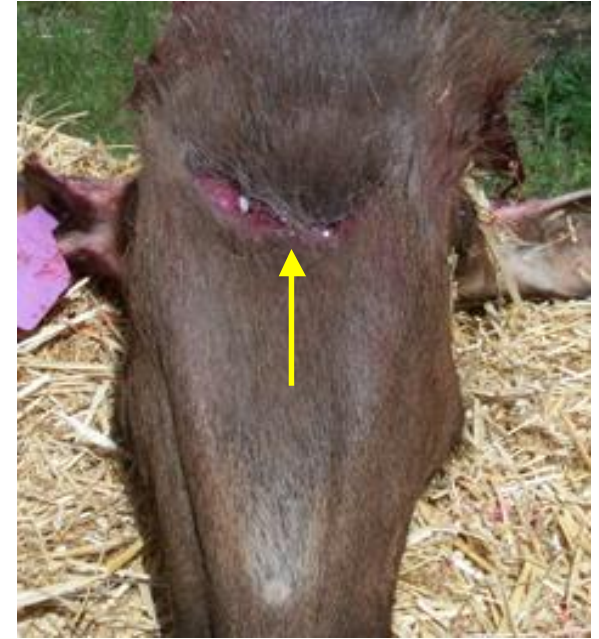
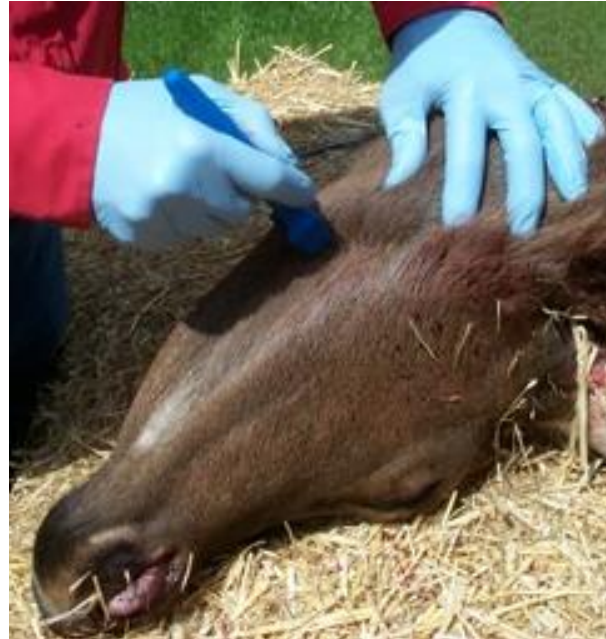
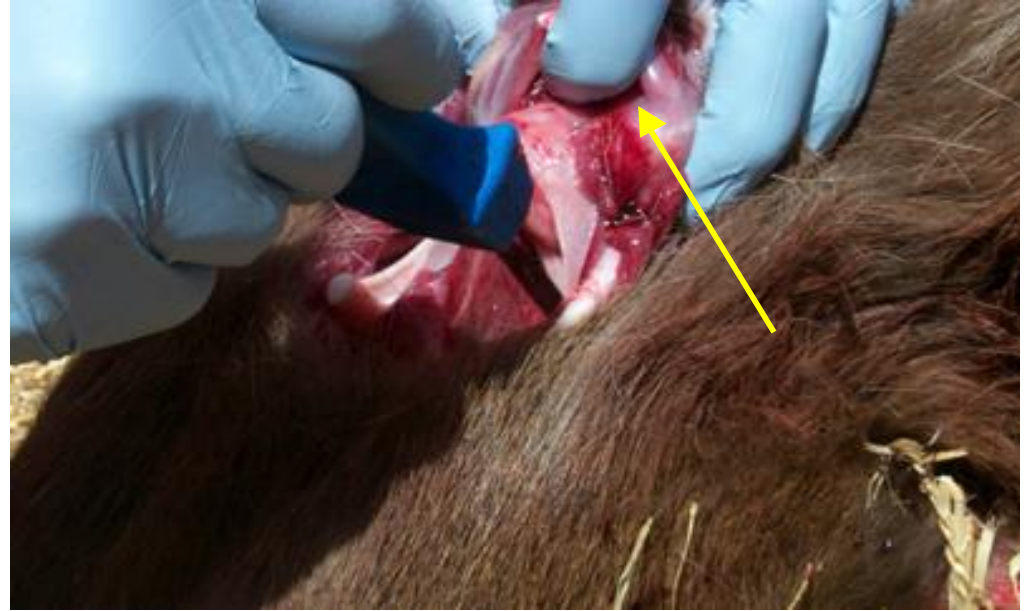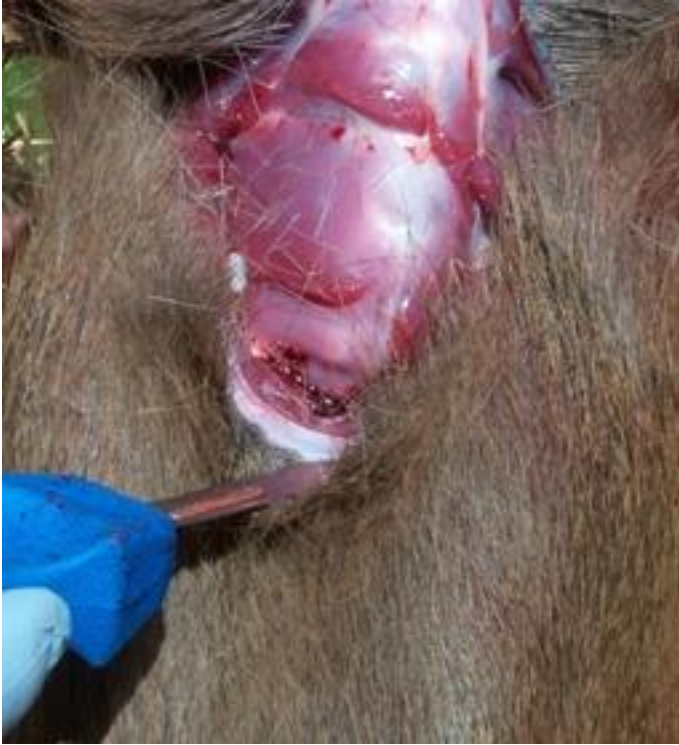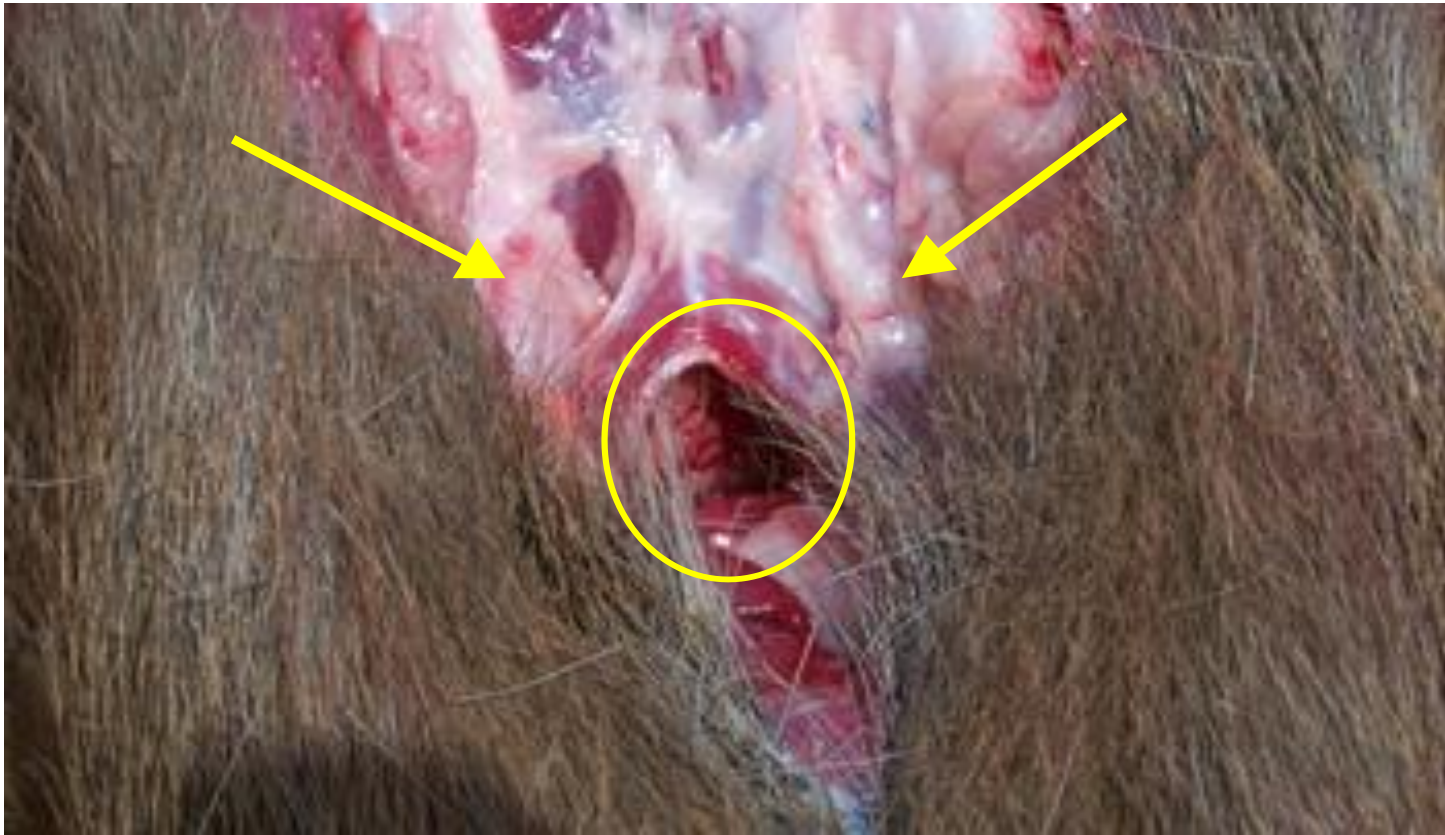
# Removal of Retropharyngeal Lymph Nodes for CWD Testing



The head does not have to be removed from the body to remove the retropharyngeal lymph nodes. Place the head upside down and make a “U” shaped incision just behind the angle of the lower jawbone. Insert the scalpel blade about as deep as it can go.

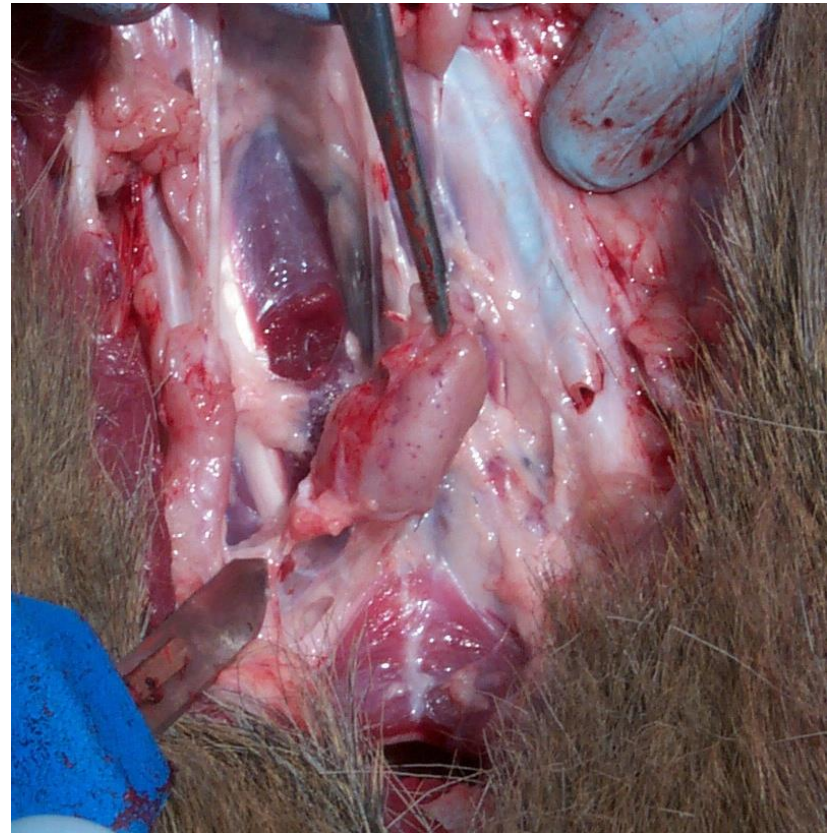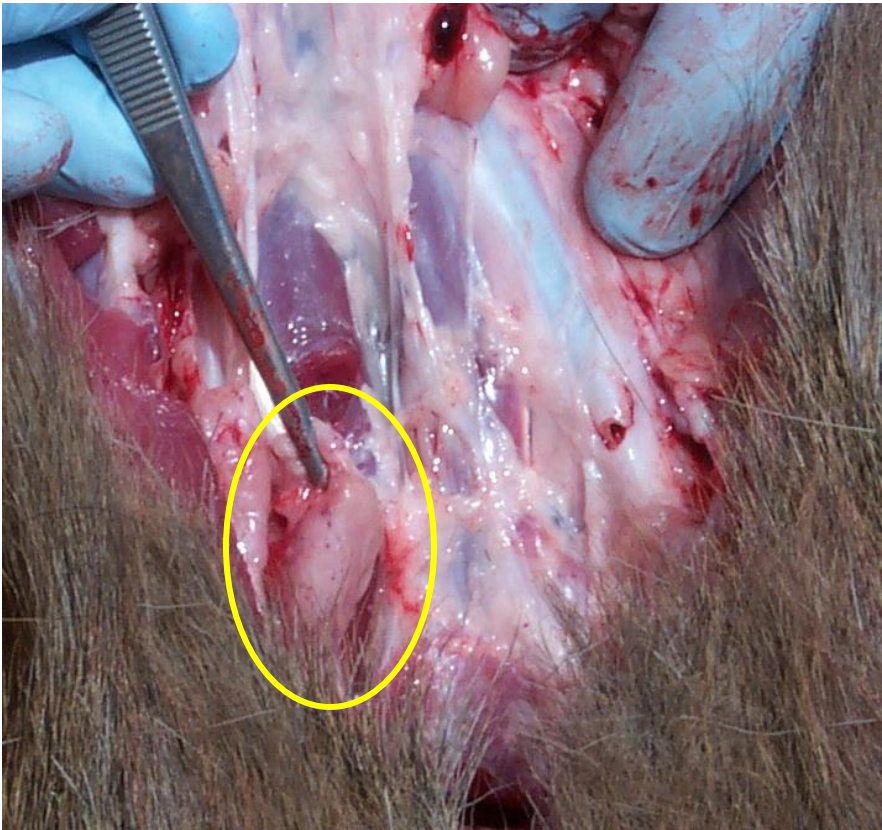


Peel the skin back. Sever the trachea and pull it rearwards while cutting connecting tissue to free the trachea and expose the underlying tissue.

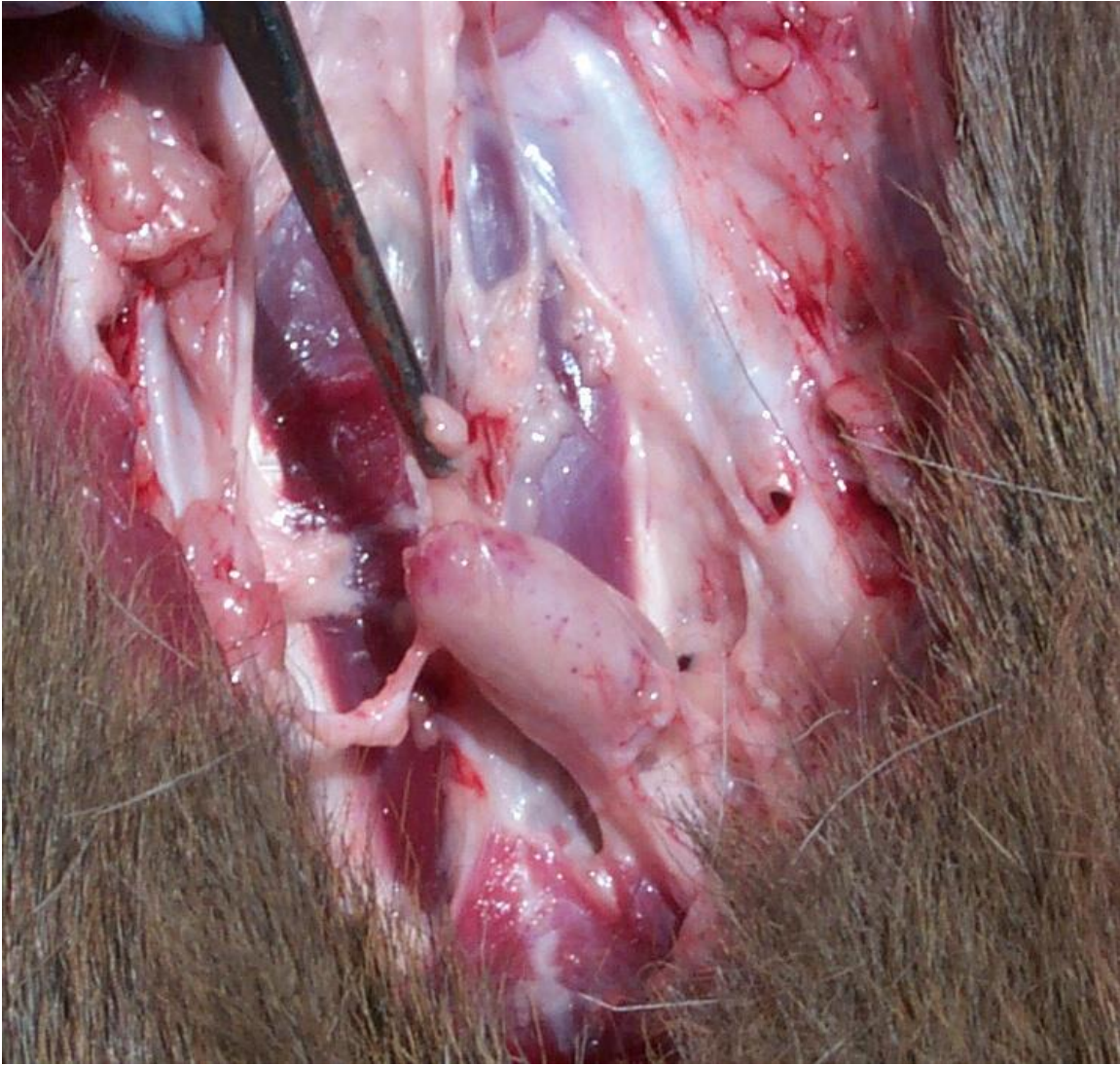

Once the trachea and esophagus are pulled backward, start exploring both sides of the forward part of the incision for the sites of the retropharyngeal lymph nodes (arrows). The nodes are located just behind, and to the sides of, the opening to the pharynx



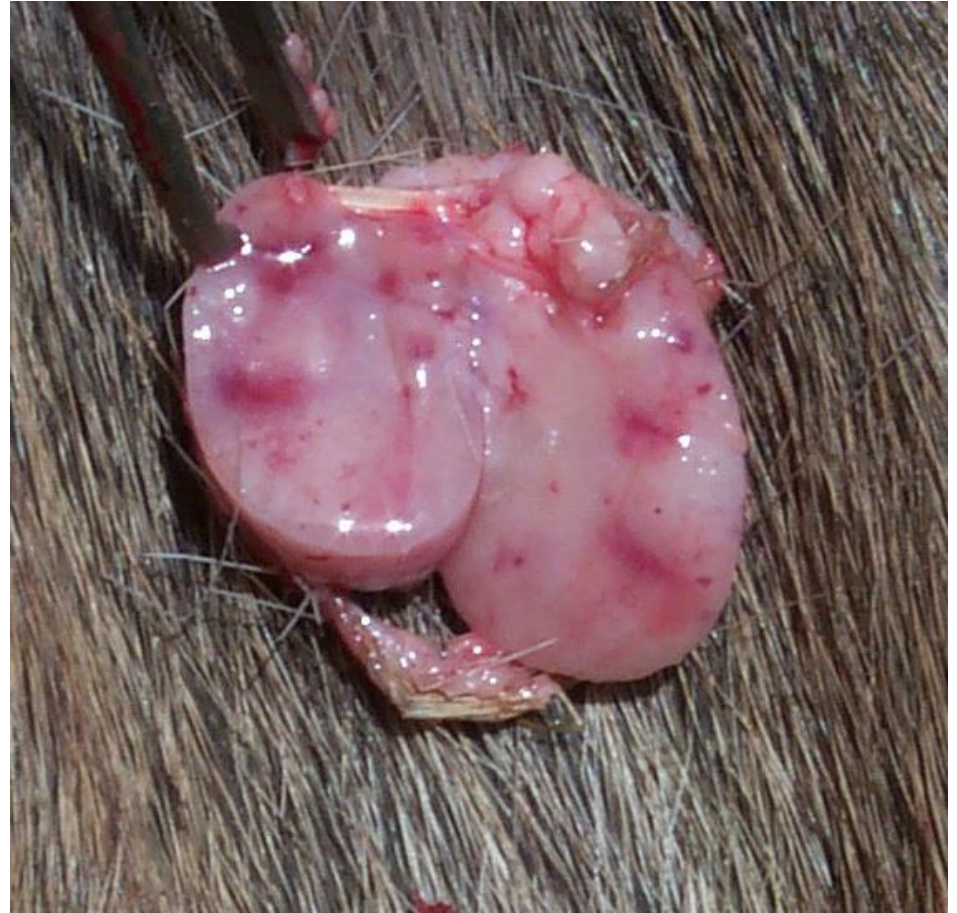
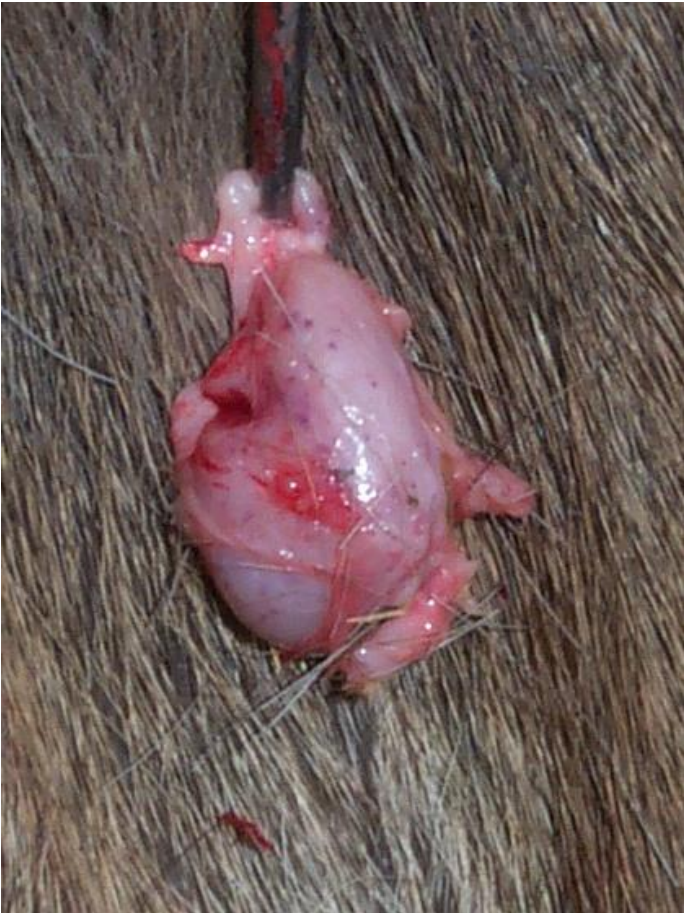
Clear away tissue from around the lymph node. Grasp the node with forceps (circle); pull on the node while freeing connecting tissue with scalpel.



cutting away tissue until node can be removed. Remove the other node in the same manner.





Examine the node when removed. It will be fairly firm and about the size of the first joint of your index finger. If still not sure that you have the node (some fat can look like a lymph node), cut into it. The cut surface should show a pale background with red to dark brown spots or splotches. Note: the cut surface of lymph nodes from animals dead for awhile will appear *darker*. Place the nodes in a plastic bag and keep cool or frozen.